

# Jump Down Syndrome

By Sherman O. Canapp Jr., DVM, MS, DACVS and Donald Hulse, DVM, DACVS

“Jump down syndrome” or traumatic fragmented medial coronoid process is a condition in the elbow joint of dogs that appears to occur commonly in performance dogs. Unlike the classic condition of fragmented medial coronoid process (FMCP) affecting the elbow joints of skeletally immature large to giant breed dogs, jump down syndrome (JDS) appears to have no age or size limitations.

Jump down syndrome (JDS) is not a topic that you will find in current veterinary literature. *Clean Run* is pleased to present the first report on the condition. The authors will be publishing a subsequent paper in *Veterinary Surgery*, the official publication of the American College of Veterinary Surgeons and European College of Veterinary Surgery.

## Anatomy

Long bones, like those that compose the elbow joint, have three parts: the marrow, which fills the interior, compact bone, which makes up the walls of the shaft of the bone, and trabecular bone, the spongy-appearing bone that is located beneath the joints in long bones. The articular surfaces of bones are covered with a smooth cartilage that allows the bones to move against each other with a minimum of resistance. The specialized connective tissue that surrounds a joint, the joint capsule, not only provides mechanical support to the joint, but also has an interior surface that secretes a viscous fluid that lubricates the joints. The elbow joint is composed of three bones (radius, ulna, and humerus), which must all grow together and fit perfectly for the elbow joint to function properly. The radius is the main weight-bearing bone. The ulna serves more as a lever arm for the extensor muscles of the elbow joint. The normal elbow joint is characterized by a smooth transition from the ulnar articular (joint) surface to the radial surface. The medial coronoid process of the ulna sits level with or slightly below the surface of the radius as shown in [Figure 1](#).

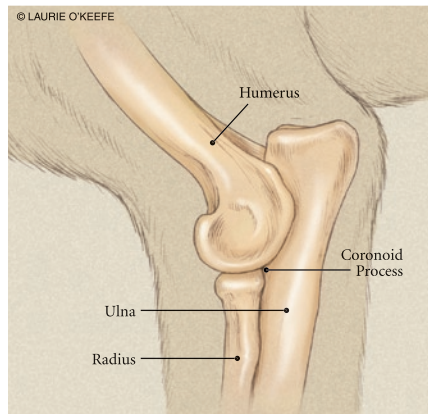


Figure 1. Normal anatomy of the canine ulna

## History and Clinical Signs

Dogs with JDS may present with a history ranging from a subtle intermittent off-loading of the forelimb to significant unilateral or bilateral forelimb lameness. This lameness is typically exacerbated with exercise and heavy activity. The onset of lameness is insidious. As lameness persists, it may increase in severity. Affected dogs often place the carpus in an exaggerated valgus position (turned out) when sitting or standing, and circle the foreleg outward and move the elbow away from the midline (circumduct the antebrachium and abduct the elbow) during the swing phase of the stride. The history of dogs with JDS typically includes a lack of response to rest and non-steroidal anti-inflammatory drugs (NSAIDs). Many dogs with JDS are mistakenly treated for shoulder pathology because the attending veterinarian elicits a pain response when the shoulder is extended. The authors believe the pain response actually arises from the elbow because when the veterinarian performs an extension maneuver of the shoulder, the elbow is usually simultaneously extended. Extension of the shoulder and elbow causes tension in the biceps/brachialis muscle complex. Tension in the biceps/brachialis exerts pressure on the medial coronoid and overlying inflamed joint capsule causing the pain response.

## Pathogenesis

The cause and pathogenesis of JDS are poorly understood. It is possible that abnormal repetitive loading, such as landing from a jump, hitting contacts or a flyball box, and so on, may lead to microfractures of the bone underneath the cartilage (subchondral fractures). Additionally, increased repetitive loading can arise from contraction of the biceps/brachialis muscle complex. When the biceps/brachialis contracts, a force is generated that rotates the medial coronoid into the radius. These microcracks disturb the mechanical properties of bone, and if not repaired properly through normal body mechanisms, fatigue fractures develop. Additionally, loss of osteocytes (bone cells), indicated by decreased osteocyte densities, has been strongly associated with the presence of microdamage after fatigue loading. These studies imply that excess load may lead to fatigue microdamage of the subchondral trabecular bone and eventual fracture, which may play an important role in the pathogenesis of JDS. Dogs may be further predisposed to this condition if they have elbow dysplasia. Dogs with elbow dysplasia had asymmetric growth of the radius and ulna during development, resulting in elbow joint incongruity. Elbow incongruity such as radioulnar step defects, humero-ulnar incongruence/conflict, and varus deformity of the humerus causes abnormal contact patterns in the elbow, specifically at the coronoid trochlear articulation, which is theorized to increase the load on the medial coronoid process (MCP).

Regardless of the etiology, if left untreated as a continual lameness, secondary osteoarthritis may progress as noted by damage to the cartilage such as softening, fibrillation, fissuring, and erosions as well as additional subchondral bone microcracks and fragmentation. The free fragments contribute to frictional abrasion (“kissing lesions”) of the opposing surface including the medial aspect of the humeral condyle and radial head as seen in [Figure 2](#).

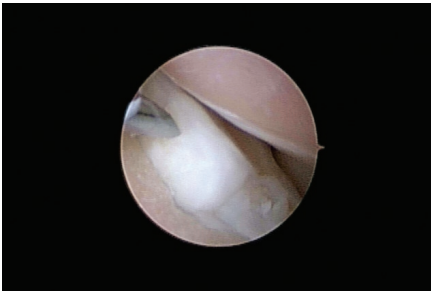


Figure 2. Chronic FCP with severe osteoarthritic progression

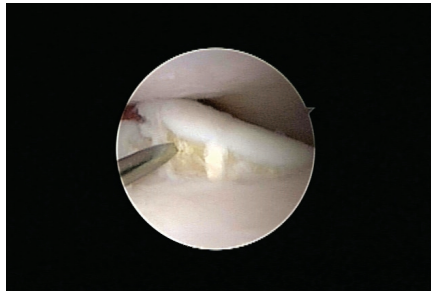

Figure 3. JDS diagnosed on arthroscopic examination

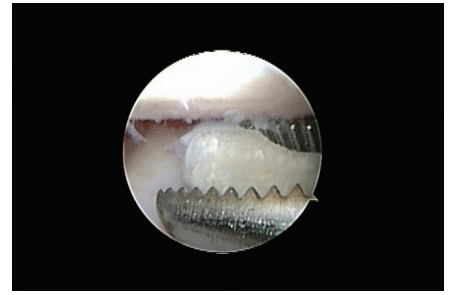


Figure 4. Arthroscopic fragment removal

## Orthopedic Examination

On physical examination discomfort is usually noted on direct palpation of the medial compartment of the elbow joint, specifically the medial coronoid process. Discomfort may also be noted on hyperflexion of the elbow. Most dogs with JDS are reluctant to allow for full end-range flexion. In chronic cases, full flexion may not be obtained. Crepitus (“popping or grinding sensation”) may be noted when placing the elbow through range of motion. Some investigators suggest that the carpus should be placed in a flexed, externally rotated position while the elbow is extended. Joint effusion (fluid leakage) may be detected as a fluctuant swelling beneath the lateral or medial epicondyle of the humerus. Depending on the chronicity, atrophy may be noted in the affected forelimb.

## Diagnostics

In addition to history, gait analysis, physical examination, orthopedic and neurologic examinations, further diagnostic tests used to differentiate causes of elbow pathology currently consist of hematology, biochemical profile, urinalysis, arthrocentesis, imaging modalities, and arthroscopy.

Unfortunately, radiographs (x-rays) have been shown to be of little value because of difficulty identifying the fragment or line of separation using standard radiography. In some chronic cases, however, radiographs may reveal secondary evidence of bony remodeling consistent with osteoarthritis. These changes may include sclerosis (thickening or hardening) within the ulnar notch, and remodeling along the anconeal process and MCP. Advanced diagnostic imaging modalities such as CT scans, MRI, nuclear scans, and arthroscopy may allow confirmation of the condition. Arthroscopic evaluation of the elbow joint allows direct observation of all major intra-articular structures with magnification, “dynamic” evaluation of tissues during elbow range-of-motion

tests, and “palpation” of intra-articular tissues using arthroscopic instrumentation. Arthroscopic exploration of the elbow provides a definitive diagnosis of JDS when a fragment or cartilage fissure is observed as shown in [Figure 3](#). In a small percentage of cases, advanced imaging (nuclear scan, CT, MRI) indicates fragmentation of the coronoid but arthroscopic observation does not reveal a fissure or fragment. In such cases, the fissures (microcracks) are believed to be within the coronoid bone beneath the cartilage surface.

## Treatment

Treatment of JDS is multimodal and includes a combination of medical and surgical management as well as rehabilitation therapy. The objectives of therapy should be to first remove the inciting cause so that medical management and rehabilitation can be effective (think of this as first taking the pebble out of the shoe). Through a multimodal approach it is possible to relieve pain and maintain limb function, as well as to return the dog to a normal level of activity.

## Arthroscopy

Arthroscopy is an excellent modality for diagnosing JDS as well as a minimally invasive means of treatment. Arthroscopic removal of the fragments is recommended not only to remove the inciting cause of lameness but also to help prevent the progression of osteoarthritis. Arthroscopic treatment may include a combination of techniques such as fragment removal, debridement of diseased tissues, creation of vascular access by abrasion arthroplasty, forage, microfracture, and subtotal coronoid ostectomy depending on the progression and severity of disease as seen in [Figure 4](#). Arthroscopy is not only a great diagnostic modality, allowing for superior visualization of structures within the joint, but also has less soft tissue trauma, shorter surgery and hospitalization times, decreased risk of infection, and shorter recovery times compared to the traditional

surgical approach of fully opening the joint.

## Medical Management

Following arthroscopic treatment, dogs are typically prescribed NSAIDs for 14 days to help decrease inflammation and discomfort. Adequan (polysulfated glycosaminoglycans), an injectable joint protective agent, is also recommended following arthroscopic treatment and is administered intramuscularly twice a week for up to four weeks. Adequan has been shown to decrease the amount of degradative enzymes (that stimulate inflammation and cartilage erosion) as well as promote repair and regeneration of cartilage. In addition, an oral joint protective agent such as Dasuquin, which contains glucosamine, chondroitin sulfate, avocado/soybean unsaponifiables (ASU), +/- methylsulfonylmethane (MSM), is recommended as a daily supplement for life. The anti-inflammatory properties and pain-reducing effects of these supplements have been well-documented. There is also evidence that they may have a cartilage-protective effect.

## Rehabilitation Therapy

Rehabilitation therapy following arthroscopic treatment includes a combination of techniques such as cryotherapy (ice therapy), modalities (such as laser therapy), manual therapies, and a home exercise program. Rehabilitation therapy is used to help decrease post-operative inflammation and swelling, build muscle mass, improve comfort and increase range of motion. This improved muscle mass and range of motion will provide long term pain relief as well as better overall function of the limb and improved quality of life. Therapy sessions are typically performed at a rehabilitation center weekly and the exercise program at home 2 to 3 times a day. Recovery following arthroscopic treatment for JDS is typically 2 to 3 months with return to sport at approximately 4 to 5 months.

## Additional Therapies

For dogs in which JDS was not diagnosed early on and significant osteoarthritis has already progressed, additional medical therapies may be required following arthroscopic treatment and rehabilitation therapy. These therapies include intra-articular injections (hyaluronic acid or cortisone) or stem cell therapy.

Hyaluronic acid (HA) is a form of visco-supplementation; that is, it helps restore the physical properties of the joint fluid to aid in lubrication, decreases the inflammation and degradation of the joint, and helps in cartilage repair. HA is administered intra-articularly (injection into the joint) under sterile conditions with the dog sedated. Injections may be performed once a week for three weeks. Clinically over 70% of dogs respond well to HA and improvement can be noted for over six months following administration. For dogs that do not

respond to HA, a series of intra-articular cortisone injections is another option to decrease inflammation and discomfort associated with osteoarthritis. Depo-Medrol (methylprednisolone acetate) and Vetalog Parental (triamcinolone acetonide) are the most commonly used. Similar to HA, intra-articular administration of cortisone is performed under sterile conditions with the animal sedated. Administration of cortisone typically results in pain relief in 12 to 24 hours and can last for weeks to months. The injections are typically performed three weeks apart and up to three to four injections can be given during a year period. Side effects are minimal; however, some dogs can be more uncomfortable the first day or so after injection. It is believed that the administration of triamcinolone may also have a cartilage protective effect in addition to decreasing inflammation in the joint.

Regenerative stem cell therapy can also be used in the management of elbow osteoarthritis. Adult regenerative stem cells are multipotent cells located in bone marrow, joint capsule, and fat tissue that are capable of maturing into bone, cartilage, tendon, or ligament cells and can be used to repair and regenerate damaged tissues such as cartilage in osteoarthritis. This is performed by harvesting cells from the fat located behind the shoulder or between the back legs. The fat is removed surgically and sent to the Vet Stem Company in California where it is purified into regenerative stem cells. Two days after the initial surgery to harvest the cells, your dog is brought back into the clinic and, under sedation, the cells are injected into the osteoarthritic joint. Clinical improvement has been noted in dogs two to four weeks after injection and improvement has been seen to last for up to two years.

### Additional Reading

Danielson K, Fitzpatrick N, Muir P, et al., Histomorphometry of Fragmented Medial Coronoid Process in Dogs: A Comparison of Affected and Normal Coronoid Processes, Vet Surg 35:501-509, 2006

*Dr. Canapp, a Diplomate of the American College of Veterinary Surgeons, completed a combined D.V.M./M.S. at Kansas State University, an internship in small animal medicine and surgery at the University of Missouri, a three-year residency in small animal surgery at the University of Florida, and training in canine rehabilitation by the Canine Rehabilitation Institute. Dr. Canapp currently practices orthopedic surgery and sports medicine at the Veterinary Orthopedic & Sports Medicine Group (VOSM) in Ellicott City, Maryland, and acts as a consultant to local zoos, police K-9 units, agility, flyball, and disc competition dogs. See additional information about Dr. Canapp at [www.vetsportsmedicine.com](http://www.vetsportsmedicine.com).*

*Dr. Hulse graduated from Texas A&M in 1970 and completed his surgical training at Kansas State University in 1973. Beginning in 1970 and continuing until his appointment as a professor of orthopedic surgery at Texas A&M University in 1984, Dr. Hulse served as a clinician in general practice and as a staff surgeon at Louisiana State University and Oklahoma State University. In 1977, he fulfilled the admission requirements for the American College of Veterinary Surgeons. He has developed techniques commonly used for treatment of bone and joint disorders in dogs and is well published in veterinary literature. His clinical research interests focus on minimally invasive surgery for joint disorders and for fracture treatment.*

## Because he's not just a pet. He's an athlete.



Veterinary Orthopedic and Sports Medicine Group (VOSM) is committed to providing the highest quality veterinary Orthopedic surgery and rehabilitative care. VOSM is the only practice in North America with a:

- Board Certified Veterinary Orthopedic Surgeon trained in Canine Rehabilitation
- Veterinarian and Physical Therapist also trained in Canine Rehabilitation
- Veterinary Sports Trainer

Through the effective integration of science, compassion, and professional integrity, we relieve pain, regain movement, restore function, and promote health and wellness in your flourishing athlete. **We not only understand the demands that are placed on your athlete, we help him meet them.**

- Sports Medicine
- Minimally Invasive Orthopedic Surgery
- Gait Analysis & Retraining
- Rehabilitative Therapy

Entrust your best friend with the best in medical care.



10975 Guilford Road, Annapolis Junction, MD 20701 • 240-295-4400 or 410-418-8446 • [www.VOSM.com](http://www.VOSM.com) • [info@VOSM.com](mailto:info@VOSM.com)