Returning to Agility Competition After Treatment for Medial Shoulder Syndrome

COURTESY OF RICH KNECHT PHOTOGRAPHY

By Sherman O. Canapp, Jr., DVM, MS, CCRT, DACVS-SA, DACVSMR
Photos courtesy of VOSM except where noted

Case Study

Lacey is a 10-year-old female spayed German Shorthaired Pointer from Staten Island, New York who presented to Veterinary Orthopedic & Sports Medicine Group (VOSM) in April of 2009 for right thoracic limb lameness. At initial presentation, Lacey had a shortened stride in her right forelimb at a walk and a trot. On physical examination, there was a significantly decreased range of motion in the right shoulder during extension. The abduction angle of the right shoulder was increased when compared to the left. Significant pain, spasm, and discomfort were noted on abduction of the right shoulder. Discomfort was noted on direct palpation of both biceps tendons and when the shoulders were flexed while the elbows were extended, also indicating biceps tendon pain. Initial GAIT4Dog® objective gait analysis revealed a decreased pressure on the right thoracic limb as compared to the left thoracic limb.

Based on the clinical signs and the physical exam findings, shoulder arthroscopy was recommended and performed in April of 2009. Arthroscopic exploration of the right shoulder revealed significant pathology to all compartments, and a medial shoulder instability. Thermal capsulorrhaphy, or radiofrequency (RF) treatment, was performed to all areas of inflammation and disruption. Significant tissue shrinkage and tightening were observed. Following treatment, Lacey was placed in a DogLeggs Shoulder Stabilization System (commonly referred to as "hobbles") for three months and entered into a dedicated rehabilitation therapy program. GAIT4Dog objective gait analysis revealed an even pressure on the right forelimb as compared to the left six months post treatment. Lacey made an excellent recovery and returned to agility eight months after her treatment. In February of 2012 Lacey earned her AKC MACH, in February of 2013 she achieved her MACH 2, and subsequently her MACH 3 in August of 2013. The German Shorthaired Pointer Club of America, an AKC Parent Club, named Lacey the Agility Dog of the Year in both 2013 and 2014. Lacey went on to earn her MACH 4 in February of 2014 and her MACH 5 in August of 2014. Lacey qualified as the #5 dog of her breed for the AKC Agility Invitational in 2013, #1 for 2014, and #3 for 2015. Lacey was rated the #1 German Shorthaired Pointer at the AKC Invitational in 2014. Lacey earned her MACH 6 in February of 2015, and her owner anticipates that she will earn her MACH 7 by the end of 2015. Lacey is currently over 6 years out and competing at her pre-injury level.

Medial Shoulder Syndrome in Agility Dogs

One of the most common causes of forelimb gait related issues and lameness in performance dogs that present to VOSM is medial shoulder syndrome (MSS). This condition may be considered somewhat similar to rotator cuff injuries in people including ligament disruption, tendinopathy, and labral and capsular tears or disruption. Unlike medial shoulder instability (MSI), these shoulders are not unstable but instead show evidence of sprain and strain injury leading to discomfort and dysfunction. Anatomically, the shoulder joint is the least stable joint in the dog, relying on soft tissue structures for stability and function. Subscapularis tendinopathy is the most common component of medial shoulder syndrome, however, other components of the shoulder joint are also commonly affected, including the craniomedial joint capsule, medial glenohumeral ligament (MGL), supraspinatus tendon, and less commonly the biceps tendon. Depending on the severity and chronicity of the instability, the cartilage may also be affected.

Signs of MSS may be as slight as performance-related problems such as missing cues or refusing tight turns, or be as severe as a weight-bearing lameness. The exact cause of MSS is unknown, but is thought to be related to chronic repetitive activity, or overuse, rather than trauma. Sporting athletes that participate in activities such as agility undergo extreme stresses on their muscles, ligaments, and tendons. Repetitive activities in agility dogs, such as jump-turn combinations and weave poles, place the shoulder near its end range of abduction, stressing the soft tissues of the medial shoulder complex. Additionally, events such as slipping on wet surfaces, mishaps on the dogwalk, teeter, or A-frame may also contribute to the trauma inflicted on the



COURTESY OF RICH KNECHT PHOTOGRAPHY

Lacey competing in agility. (Courtesy of Sandy and Sid Gonchar)

shoulder while participating in agility. Overuse can lead to degeneration of the shoulder support structures thus decreasing their tensile strength predisposing them to fraying, disruption, and eventually complete breakdown.

Diagnostics and Treatment

Treating the condition early is important to prevent further shoulder instability and osteoarthritic progression. The shoulder abduction test allows for a pre-operative diagnosis of MSS, and is performed by placing the elbow and shoulder in full extension with concurrent abduction of the forelimb. In addition, diagnostic musculoskeletal ultrasound can further support the diagnosis of MSS. Shoulder arthroscopy is a minimally invasive procedure that allows for complete evaluation of all major intra-articular structures within the shoulder joint using magnification, active range of motion in real time to watch the tissues engage, and arthroscopic instrumentation, and is considered the gold standard in MSS diagnosis. If MSS is identified, it can be treated arthroscopically at the same time.

Based on the results of the orthopedic examination, abduction angle tests, and arthroscopic scoring, patients are placed into one of three treatment categories: mild, moderate, or severe. Dogs with mild pathology are placed in a DogLeggs Shoulder Stabilization System ("hobbles") for two to three months and entered into a dedicated rehabilitation therapy program. Dogs with moderate pathology, like Lacey, are treated arthroscopically with thermal capsulorrhaphy, or radio frequency (RF) treatment, placed in "hobbles" for two to three months, and entered into a dedicated rehabilitation therapy program. Dogs with severe pathology are treated with RF treatment, reconstruction and stem cell therapy depending upon the severity, as well as "hobbles" and a dedicated rehabilitation therapy program.

The current technique for RF treatment in dogs has been developed based on current application in humans in which a single pass striping technique is utilized versus a multi-pass paintbrush technique due to detrimental effects that can occur with aggressive application. Tissues treated with RF become weaker than pre-treatment before they become stronger and, therefore, must be protected. There is a delicate balance between too much immobilization and insufficient immobilization, as the former can result in joint stiffness and muscle contracture, and the latter can result in stretching and recurring laxity of the treated tissues. Recovery generally ranges from three to four months, and return to training at four to six months. Second-look arthroscopy has been performed in numerous cases as requested by owners prior to entering back into agility to confirm healing. Second look arthroscopy has revealed areas of neovascularization (new blood supply to the site of injury), a tighter joint capsule, healed tendon, and no residual or negative effects to surrounding tissues or cartilage.

Return to Agility Competition

Return to competition and sport is a well-accepted measure of successful surgical outcome in human and equine literature. Dog agility involves speed, sharp turns, and jumps, and provides an excellent comparison to human and equine athletes. VOSM is in the process of conducting a retrospective study on the return to agility following RF treatment for MSS using the VOSM Return to Agility Grading Scale. The goal is to determine if agility dogs were able to return to competition, and if they were able to do so at the same performance level as they had prior to injury.

Of the greater than 500 cases of MSS treated at VOSM since 2007 from around the United States, 90 of those cases were agility dogs. A survey was sent to all owners via e-mail or was completed

VOSM Return to Agility Grading Scale

Grade	**Post-Surgical Procedure**
Grade 1	Owner chose not to return dog to agility for reasons unrelated to surgery
Grade 2	Dog was physically unable to return to agility
Grade 3	Dog returned to agility but performed worse than pre-operative level
Grade 4	Dog returned to agility and performed at pre-operative level
Grade 5	Dog returned to agility and performed better than pre-operative level

Normal anatomy of the medial aspect of the canine shoulder.

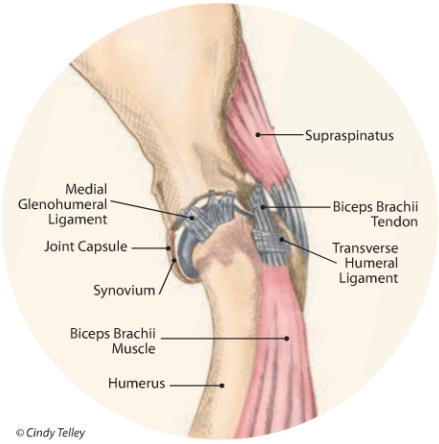

Normal shoulder anatomy medial aspect demonstrating the subscapularis muscle and tendon unit.

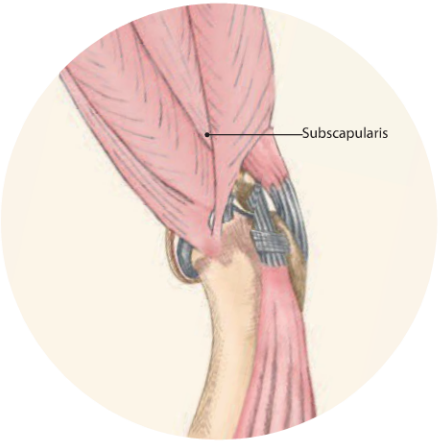

Shoulder abduction test being performed on a Border Collie with MSS.



Normal arthroscopic ÿndings.

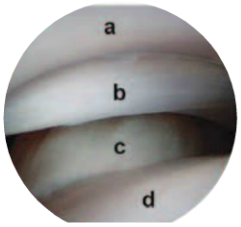

A

a. Articular surface of the glenoid cavity

b. Medial glenohumeral ligament (MGL)

c. Subscapularis tendon

d. Articular surface of humeral head

B

a. Articular surface of glenoid cavity

b. MGL

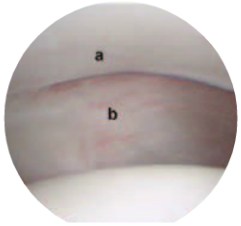

C

a. Articular surface of glenoid cavity

b. MGL/Joint capsule

Arthroscopic ÿndings in a dog's shoulder with MSI.

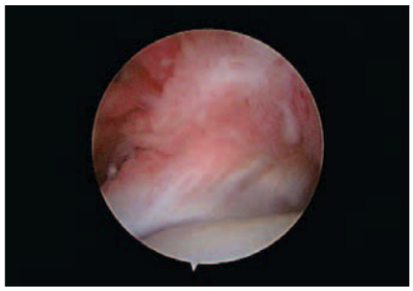

Subscapularis tendon disruption and hypertrophy Compare to A:c above

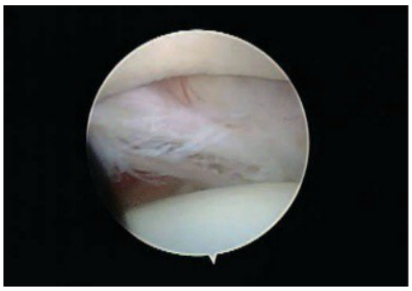

Medial Glenohumeral ligament fraying. Compare to A:b and B:b above

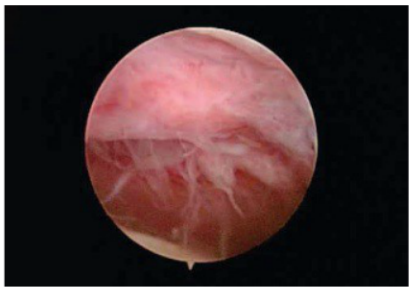

Severe synovitis and joint capsule hypertrophy Compare to C:b above

Arthroscopic radiofrequency being performed on a dog.

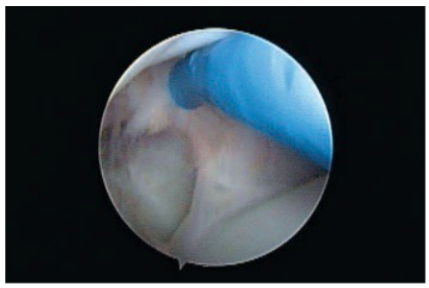

over the phone to collect information to gauge performance based on parameters including ability to return to normal activities of daily living, return to agility time, pre- and post-operative jump height and average yards per second, and average number of dropped bars per run. From the surveys collected to date, all but one respondent agreed that their dog was able to return to normal activities of daily living after MSS treatment. The respondent that disagreed was due to a subsequent injury that was never treated, and unrelated to the shoulder injury. A significant amount of dogs were able to return to agility within 10 months of treatment for MSS. Of the dogs that did not return to agility, all respondents stated that they did not return their dogs due to reasons not related to the MSS treatment. These reasons included no desire to pursue agility, an unrelated injury after MSS treatment, fear of damage to treated shoulder, fear of damage to opposite shoulder, and death due to an unrelated condition. Using the previously established VOSM Return to Agility Grading Scale (Table 1) and surveys collected to date, we found that greater than 80% of dogs that returned to agility were performing at the same level or better than they had prior to injury (Grade 4-5).

Conclusion

Appropriate post-operative care is a critical factor in dogs with MSS treated with RF treatment and it is imperative to protect the shoulder during this period. Many studies have shown the benefits of a regimented rehabilitation therapy program following MSS treatment. Owner compliance, rehabilitation therapy, and return to sport training all contribute to a successful return to agility.

The retrospective study at VOSM is ongoing. If your dog participates in agility and has received treatment for MSI at VOSM, please contact Katie Cox at kcox@vosm.com to be included.

Acknowledgements

I would like to acknowledge with much appreciation Sandy and Sid Gonchar for allowing VOSM to share Lacey's story.

Sherman O. Canapp, Jr., DVM, MS, CCRT, DACVS-SA, DACVSMR, originally from Maryland, completed a combined Doctor of Veterinary Medicine/Master of Science at Kansas State University, an internship in small animal medicine and surgery at the University of Missouri, and a three-year residency in small animal surgery at the University of Florida. Dr. Canapp currently practices orthopedic surgery and sports medicine at Veterinary Orthopedic & Sports Medicine Group in Annapolis Junction, Maryland, where he is chief of staff. Dr. Canapp has earned diplomate status from both the American College of Veterinary Surgeons and the American College of Veterinary Sports Medicine and Rehabilitation. His primary focus and research is in arthroscopy, regenerative medicine, and sports medicine. Dr. Canapp lectures nationally and internationally, and is a consultant for numerous organizations and medical companies. Dr. Canapp is also the president of Orthobiologic Innovations, LLC, which is dedicated to research and development in sports medicine and regenerative medicine.