

Superficial Digital Flexor Luxations in Performance Shelties

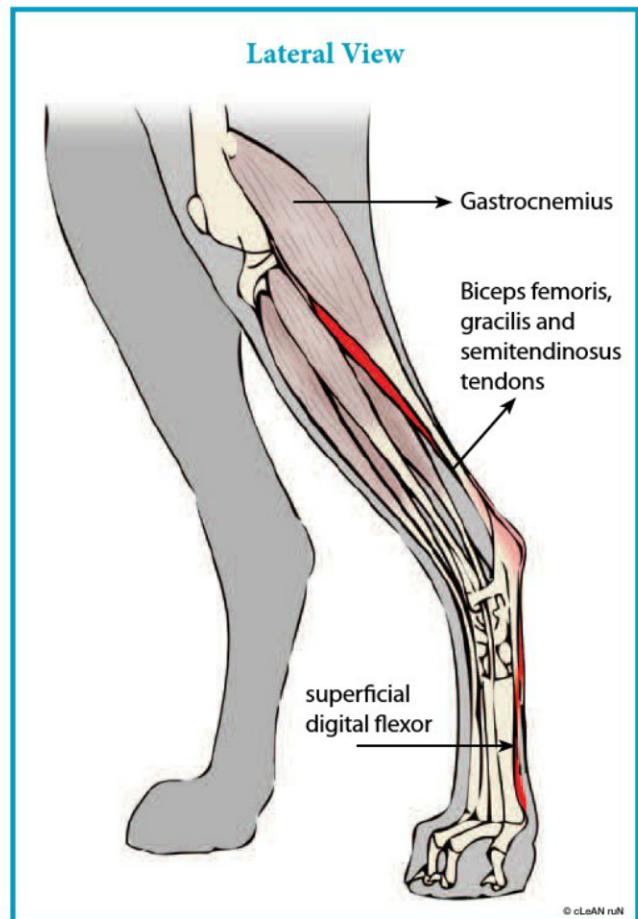
David Dycus, DVM, MS, CCRP; Diplomate, American College of Veterinary Surgeons and Sherman O. Canapp, Jr., DVM, MS, CCRT; Diplomate, American College of Veterinary Surgeons; Diplomate, American College of Veterinary Sports Medicine and Rehabilitation

Nova is a three-year-old intact female Sheltie that competes in agility. Her owner reports that beginning about four weeks prior to examination, Nova would skip during agility training on the right hind limb. An intermittent lameness was also noted when Nova would leave the weave poles and she would make wide sweeping turns. During agility runs the lameness was inconsistent; there were periods of Nova being sound, while at other times Nova would exhibit a skipping lameness. After a visit with her primary care veterinarian, Nova was rested for two weeks and prescribed an anti-inflammatory. Following two weeks of restriction, Nova was returned to training where the intermittent skipping lameness was noted again. At times, Nova's owner could hear a "popping" sound while Nova was running.

Given that Nova failed to improve initially, she was presented to the orthopedic and sports medicine service at Veterinary Orthopedic and Sports Medicine Group in Annapolis Junction, Maryland. Upon initial gait evaluation, Nova exhibited an intermittent lameness with a distinct popping sound. Her objective gait analysis using the GAIT4Dog® pressure-sensing walkway, revealed her to be offsetting weight from the right hind limb when compared to the left hind limb. Because of this, Nova was placing excessive pressure on the left hind limb and the left front limb. During manipulation of the right hock, the superficial digital flexor tendon could be luxated laterally (towards the outside) as the hock was flexed and internally rotated. As the hock was extended, the superficial digital flexor tendon could be reduced. The tentative diagnosis for Nova was a lateral luxation of the superficial digital flexor tendon due to a medial retinacular tear.

Presentation of Injury

The superficial digital flexor (SDF) tendon is a portion of the common calcanean tendon (Achilles tendon). Components of the Achilles tendon are the tendons of the gastrocnemius (calf) muscle, the combined tendons of the gracilis, semitendinosus, and biceps femoris, and lastly the tendon of the SDF. Many Achilles tendon injuries involve either complete disruption due to either a traumatic rupture or a partial disruption of one of the components typically due to an a traumatic rupture. Luxation of the SDF is another manifestation that can affect the hock (ankle) causing intermittent to consistent lameness.



Originating from the thigh bone (femur), the SDF courses down the hind limb, over the calcaneus (heel bone), and attaches to the digits to allow the toes to flex. Where it passes over the heel bone, there is a groove that the SDF lays in. On either side of the SDF tendon there is a holding layer of tissue called the retinaculum. This holding layer of tissue prevents the tendon from slipping out of its groove. Further complicating the matter is that the groove in some dogs will be shallow or absent. Spontaneous rupture of the retinaculum will cause the SDF tendon to luxate from its groove in either a medial (to the inside) or lateral (to the outside) direction. It has been noted that the medial retinaculum is less well defined and thus more prone to rupturing.

SDF luxation is associated with vigorous activity and may be caused by rotational forces directly to the tendon where it is crossing the heel bone. Such rotational forces are noted during agility training and competing. Shelties and Collies are most commonly affected; however, racing Greyhounds can also be affected. Much like the presentation of a patella (kneecap) luxation, dogs will not exhibit any lameness if the SDF is in its correct location. They will, however, exhibit various degrees of lameness when the SDF is luxated. Some owners may report a "popping" noise or note that during agility events their dogs will intermittently skip or carry the leg.

To diagnose an SDF injury, a veterinarian should perform a gait analysis by watch-

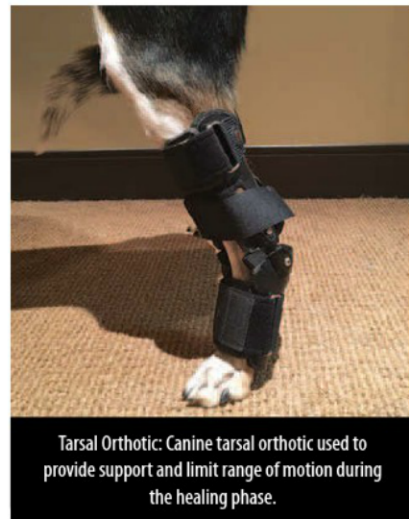ing your dog at the walk, trot, and performing various activities. In acute cases dogs may show signs of lameness with swelling noted at the point of the hock. In more chronic cases, dogs may have various degrees of lameness and even be sound during an examination. With disruption of the retinaculum, the tendon can be manually luxated during an orthopedic examination. With long-standing injury, the tendon may become affixed in an abnormal position and not be reduced. Radiographs (x-rays) may only reveal swelling in the area of the hock, but findings are rather non-specific. Diagnostic musculoskeletal ultrasound is extremely helpful in documenting not only the injury, but the severity of the injury.

Treatment of SDF Luxation

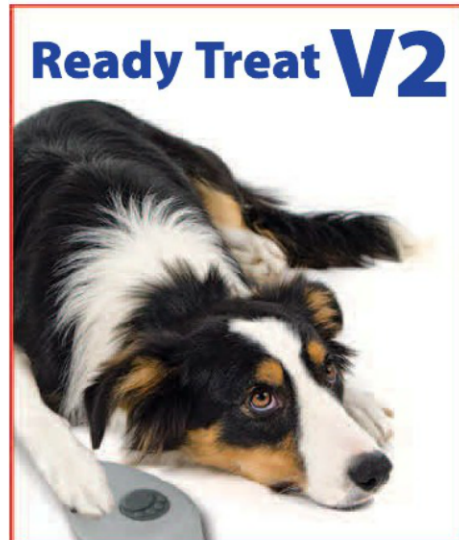Treatment usually consists of surgical repair of the retinaculum, followed by immobilization of the hock either with a splint or a custom tarsal wrap or orthotic. To surgically correct the retinaculum, a small incision is made on the side of the tear. Once identified, the SDF is reduced and the retinaculum is then sutured closed. Following surgery it is imperative that the surgical site along with the hock is immobilized to prevent undue stress on the retinaculum. Exercise restriction is vital to allow the surgical site to heal and prevent premature breakdown of the retinaculum. In our practice at VOSM, following surgery we place patients in a custom-made lateral fiber glass splint for two to four weeks.

Following this period, patients are placed in a custom tarsal wrap with thermoplast or a custom tarsal orthotic for four to six weeks. Rehabilitation therapy is recommended beginning two to four weeks following surgery. Rehabilitation therapy at VOSM consists of formal rehabilitation therapy sessions with our veterinary rehabilitation therapists, and an at-home exercise program to be performed daily.

Slow return to normal companion activity is typically allowed eight weeks after surgery. This controlled return to companion activities should take approximately two to four weeks. Once the canine athlete is back to companion activities comfortably, then a sport-specific conditioning program should be initiated. The prognosis following surgery is excellent; however, attention needs to be paid to the opposite hind limb as the same condition can occur.



Tarsal Orthotic: Canine tarsal orthotic used to provide support and limit range of motion during the healing phase.



Ready Treat V2

Deliver Treats at a Distance

What's New?

- Radio control for improved range
- Works as well outdoors as indoors

What's the Same?

- Small & lightweight
- Works with any kind of treat
- Opens immediately (no lag time)
- Simple to use: push the button to open the door



www.cleanrun.com

www.clipandgoagility.com

SDF Surgical Repair in Agility Dogs

Following Nova's orthopedic examination, she underwent radiographs of the left and right hocks. Slight swelling of the soft tissues at the point of the heel was noted on the right hock. Following radiographic examination, Nova underwent a diagnostic musculoskeletal ultrasound of both Achilles tendons to determine the extent of injury and if there was any involvement of other structures. The ultrasound of the left Achilles was normal with a normal appearance of the medial and lateral retinaculum. The calcaneal groove (the groove at the point of the heel where the SDF passes) was noted to be underdeveloped on the left side. The right Achilles was normal in tissue architecture; however there appeared to be a tear in the medial retinaculum that was allowing displacement of the SDF laterally. The calcaneal groove was noted to be underdeveloped on the right side. The under-development of the calcaneal groove has been reported in Shelties and is one of the pre-disposing factors leading to luxation of the SDF.

Given that Nova had a clinical lameness that was affecting her performance, she was recommended to undergo surgical correction. Prior to surgery measurements were taken to order Nova a custom tarsal wrap. In surgery, a small incision was made on inside of the right hind limb just adjacent to the point of the heel. The damaged retinaculum was found and sutured back together to ensure the SDF could not luxate. Following surgery, Nova was placed in a custom fiber glass splint while awaiting delivery of her custom tarsal wrap.

Nova was able to be discharged from the hospital the day following surgery with instructions for exercise restriction. These restrictions include no running, jumping, playing, or training. She was taken outside on leash at all times. Her bandage was changed every five to seven days for the next two weeks. Two weeks following surgery, Nova's custom tarsal wrap arrived. She was placed in the tarsal wrap and thermoplast (a hard moldable plastic) was molded to fit her anatomy. The thermoplast was held in place by Velcro straps on the tarsal wrap. At this point Nova was entered into a formal rehabilitation program twice weekly along with a home exercise program. Her formal rehabilitation initially consisted of manual therapies, which included passive range of motion of all her limbs, therapeutic massage along with laser therapy to the surgical site and along any sites of muscle tightness (due to compensation). At home Nova was walked two to three times daily on leash beginning for five minutes and increasing by five minutes weekly. Her owner was also instructed to begin performing light isometric exercises once to twice daily to maintain flexibility, balance, and muscle strength. Four weeks following surgery, Nova's rehabilitation therapy consisted of manual therapies with therapeutic exercises geared towards improving and building muscle mass along with maintaining flexibility and balance. Her leash walks and at home exercises were increased.

At eight weeks following surgery, Nova was introduced to hydrotherapy (underwater treadmill) once to twice weekly. Hydrotherapy was used to continue building up muscle mass and work on endurance. At ten weeks following surgery, Nova was allowed to begin supervised activity at home with the tarsal wrap off. Her leash walks were continued with the tarsal wrap on, but consisted of introducing inclines, declines, and uneven terrain.

Nova's final recheck examination was performed at twelve weeks after the surgical correction. During this examination no lameness was detected at a walk and her objective gait analysis revealed her to be distributing even pressure to all four limbs. During manipulation of the SDF, the tendon could not be luxated and range of motion in the right hock was normal and comfortable. Nova was cleared to begin slow return to companion status without the tarsal wrap over the course of two weeks. Beginning at 14 weeks after surgery, she was entered into a sport-specific conditioning program.

This sport-specific conditioning program was designed to allow Nova to develop endurance and muscle memory specific to agility. Furthermore, the conditioning is designed to prevent Nova from re-injury as well as prevent the same injury on the left hock.

Approximately 18 weeks after surgery, Nova was back to agility training and was able to compete in the following months with no evidence of lameness, discomfort, or skipping. 🐾

Dr. David Dycus attended Mississippi State University's College of Veterinary Medicine. After earning his Doctor of Veterinary Medicine, he then completed a rotating internship, and returned to Mississippi State for his surgical residency, simultaneously completing his Master of Science. Dr. Dycus then earned diplomate status with the American College of Veterinary Surgeons. Dr. Dycus is also a Certified Canine Rehabilitation Practitioner through the University of Tennessee. With these skills, Dr. Dycus currently practices orthopedic surgery and sports medicine at Veterinary Orthopedic & Sports Medicine Group in Annapolis Junction, Maryland. Dr. Dycus has special interests in orthopedics and sports medicine, and frequently lectures to fellow veterinarians on these topics at both local and national conferences. To learn more about Dr. Dycus, please visit www.VOSM.com.

Sherman O. Canapp, Jr., DVM, MS, CCRT, DACVS-SA, DACVSMR, originally from Maryland, completed a combined Doctor of Veterinary Medicine/Master of Science at Kansas State University, an internship in small animal medicine and surgery at the University of Missouri, and a three-year residency in small animal surgery at the University of Florida. Dr. Canapp currently practices orthopedic surgery and sports medicine at Veterinary Orthopedic & Sports Medicine Group in Annapolis Junction, Maryland, where he is chief of staff. Dr. Canapp has earned diplomate status from both the American College of Veterinary Surgeons and the American College of Veterinary Sports Medicine and Rehabilitation. His primary focus and research is in arthroscopy, regenerative medicine, and sports medicine. Dr. Canapp lectures nationally and internationally, and is a consultant for numerous organizations and medical companies. Dr. Canapp is also the president of Orthobiologic Innovations, LLC, which is dedicated to research and development in sports medicine and regenerative medicine.