

Shoulder Conditions in Agility Dogs

By Sherman O. Canapp, Jr., D.V.M., M.S.,
Diplomate ACVS

Photos courtesy of Sherman Canapp

© MATTALLISONPHOTOGRAPHY.COM

The shoulder joint is an intricate network of interlinked support mechanisms especially designed to withstand large forces, to provide extraordinary mobility, and yet to maintain the stability and control necessary to enable precise function of the forelimb during agility competition. With the coordinated action of over 25 muscles required for shoulder motion, the ensuing action is complex with the limb undergoing components of flexion, extension, rotation, abduction (movement away from the center of the body), and adduction (movement toward the center of the body). The potential for muscle injuries causing performance issues and lameness is significant when all muscular contributions to the joint are considered. When strain injury occurs during agility activities from overstretching and overuse, muscle

fibers can be disrupted, most commonly near the muscle-tendon junction. These injuries are typically characterized by initial inflammation and pain, followed by healing with marked scar tissue, impeding the ability of the tendon to stretch.

Muscle strains are the most frequent injury in human sports, producing a range of injury from tearing a few muscle fibers with pain and local spasm to complete muscle rupture. Strength of muscle contraction is greatly affected by even minor strain injury. Acute muscle injuries rarely have been reported in the canine veterinary literature, and discussion of chronic muscle disorders in dogs is limited to a handful of classical syndromes or inflammatory conditions. Given the similarities between the human and canine musculoskeletal system, it seems likely that such common injuries

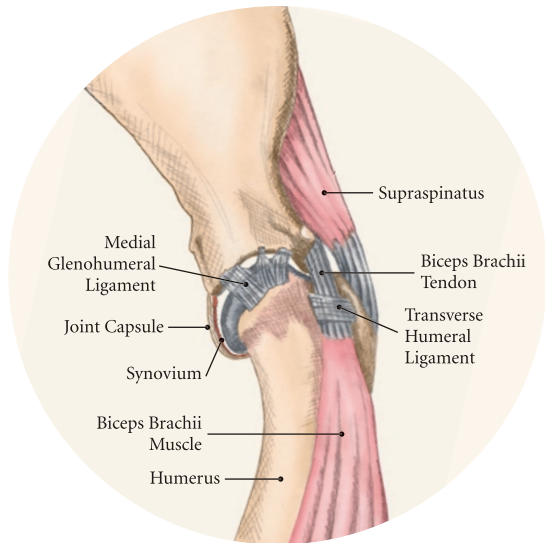
in human athletes would also be common in their canine athlete counterparts. The low reported prevalence of muscle injury in dogs is probably due to a failure to diagnose the condition.

Inflammation and edema (increased fluid in the tissues) play a large role in muscle strains. Although the ability of the muscle to contract is substantially affected, recovery appears to be rapid. Some muscle fibers regenerate, but normal microscopic structure is not restored and scar tissue persists.

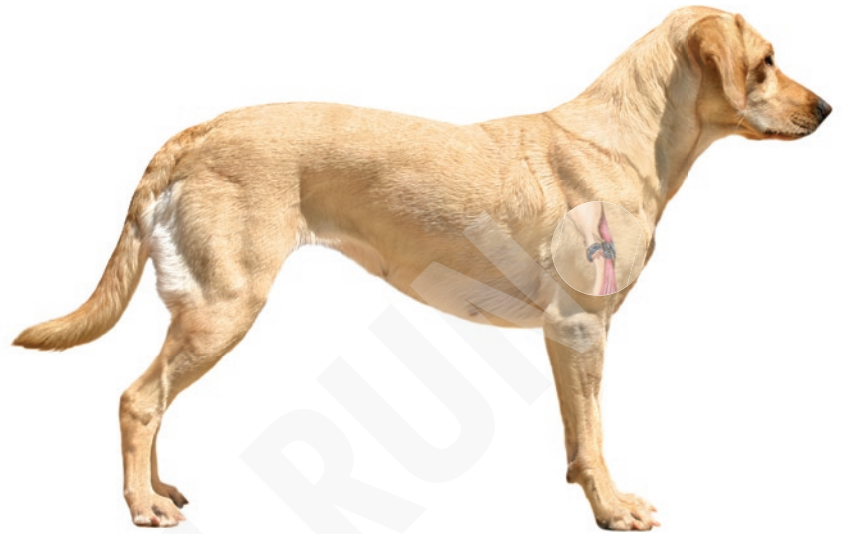Healing of the muscle by scar tissue predisposes it to reinjury and possibly to muscle contracture or permanent shortening. Muscle strains have been reported in every major muscle group of the forelimb, but the muscles at particular risk in Agility Dogs are the biceps brachii and the supraspinatus.

> Bicipital Tenosynovitis

One of the most frequent shoulder conditions seen in Agility Dogs is bicipital tenosynovitis (BT), which involves the biceps brachii muscle and its tendon that crosses the shoulder joint. The biceps flexes the elbow and extends and stabilizes the shoulder joint during standing or during the weight-bearing phase of locomotion.



© CINDY TELLEY



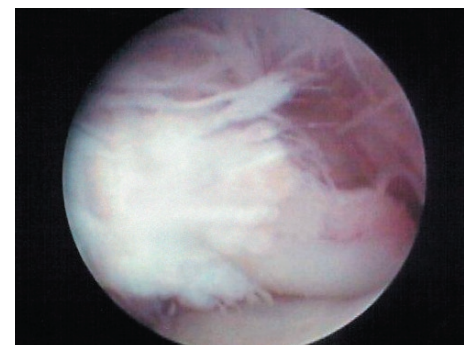
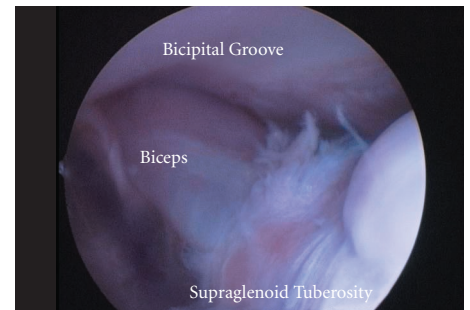
Diagnosis

Agility Dogs with BT commonly have difficulty with performing two-on/two-off contacts, knock bars with their forelimbs, or are reluctant to jump. On gait analysis, they often have a weight-bearing lameness (subtle to severe) on one side that becomes worse with activity. Pain/discomfort may be elicited by direct palpation (examination by touch) over the biceps tendon. Pain and spasm may be noted when flexing the shoulder while at the same time extending the elbow.

Unfortunately, x-rays are of minimal assistance when the injury is in its acute phase, but may reveal mineralization of the tendon when the condition is chronic. MRI (magnetic resonance imaging) and ultrasound may be used to identify the condition in acute and chronic situations. Shoulder arthroscopy, used to diagnose and treat problems inside the joint by arthroscope (a small tubular optical instrument), is a minimally invasive procedure that also may be used as a therapeutic tool.

Causes

The cause of injury in Agility Dogs appears to be related to repeated strain injury. This includes two-on/two-off contacts, landing vertically on the forelimbs from a misjudged jump, overstretching of the muscle, quick turns, and repetitive contractions of the muscle with the shoulder flexed and/or the elbow extended. Injury to the tendon can occur in a number of ways including strain from overloading, degeneration, or disruption. A single less than maximum load may injure some of the fibers without complete failure of the tendon, but the blood supply to the tendon proper is poor, leading to a longer healing time. Repetitive strain injury may initiate actual degeneration of the tendon. As the area continues to be reinjured, the tendon may weaken sufficiently for inflammation and/or microtears (tendinopathies) in the connective tissue in or around other tendons to form, ultimately leading to shoulder joint instability.



Above: arthroscopy biceps normal

Below: arthroscopy bicipital tenosynovitis severe, showing fraying and disruption of the biceps tendon.

Treatments

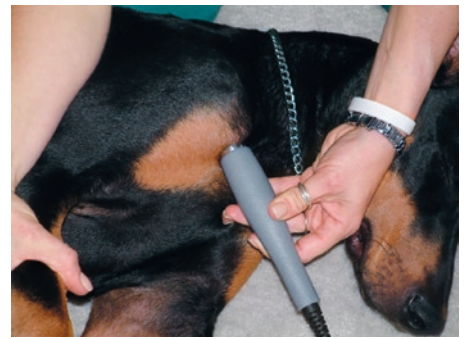Acute cases of bicipital tenosynovitis may be treated by conservative medical management and rehabilitation therapy. Conservative medical management should include controlled activity, non-steroidal anti-inflammatory drugs (NSAIDs), cryotherapy (icing), and possibly injections of hyaluronic acid or cortisone directly into the joint itself (intra-articular). To promote healing and decrease adhesion formation, laser therapy is recommended to increase circulation and to remove waste products. Acupuncture also can be used to promote healing and decrease pain levels. Initiating low load, pain-free, high repetition exercise and range of motion (ROM) movements early in the healing process is important. Pain relief and reduction of inflammation can be achieved with electrical nerve stimulation therapy. Acute tendon injuries should not be stretched because of the potential for producing more microtears due to the chemical changes in the tissue. Pain-free, passive ROM movements (flexion and extension of the limb while the dog is not weight bearing) and gentle wobble board activities (all directions, front to back and side to side), and alternating leg lifts are recommend first, with progression to active ROM exercises (weight-bearing exercises that cause flexion and extension of the limb). A strengthening program consisting of controlled leash walking, stepping over cavaletti, wobble board use, and stabilizing exercises (such as handstands on the forelimbs, slowly progressing to wheelbarrowing exercise) should follow.

With chronic BT, the inflammatory process must be reinitiated to break down scar tissue and remodel the tendon fibers into the proper orientation, which increases the tendon's load capacity. Because of the need to reinitiate the inflammatory response, NSAIDs or intra-articular corticosteroids are not recommended for chronic tendinopathies. Appropriate therapy for chronic tendinopathies includes deep cross-friction massage, heat, and ultrasound therapy. Acupuncture and laser to increase circulation and for pain control may be beneficial. The exercise progression is similar to that recommended for acute tendinopathies, but stretching after treatment is advised. Active ROM exercise such as walking for longer periods also is recommended. Because of the chronic nature of the tendon changes, your dog will usually take longer to recover and progress through the healing and exercise stages. Be sure not to become impatient and push your canine athlete too quickly.

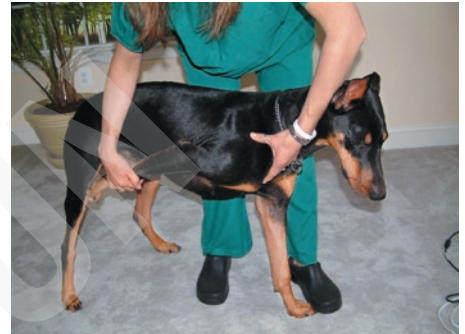Surgical treatment is recommended for chronic cases of BT that are not responsive to medical management or rehabilitation therapy. Surgical options include reattaching the tendon at a new location (tenodesis) or an arthroscopic tendon release.

Rehabilitation


Controlled activity is an important component during rehabilitation and the post-operative period and should include leash walks of increasing duration and end-stage eccentric exercises, such as walking and trotting down hills. Short periods of off-lead activity are allowed once the lameness has resolved. Toward the end of rehabilitation therapy retraining should begin. Examples of retraining techniques for BT may include starting with low, straight-line jumps with very wide sweeping turns that progress over time to higher jumps with tighter angles. Do not include the A-frame and weave poles until late in the retraining period. Be sure to start with turns toward the injured limb and progress to turns toward the uninjured limb. Following a warm-up, make sure to perform biceps stretching techniques (shoulder flexion and elbow extension). Following agility work, use an appropriate cool down with ice therapy (5 minutes on, 5 minutes off, 5 minutes on).



Biceps tendon ultrasound therapy



Biceps stretch



Cavaletti

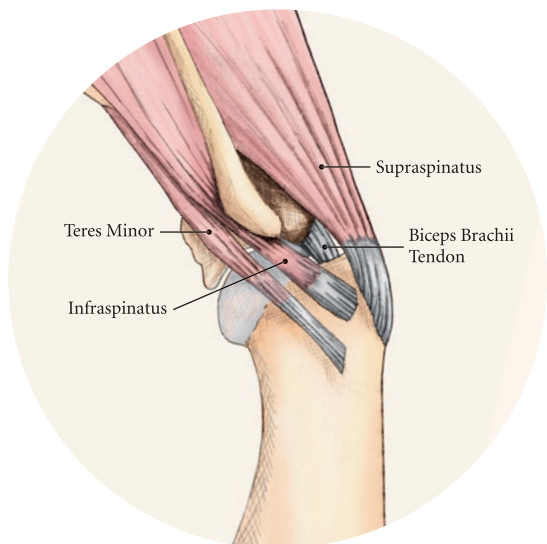


Handstands

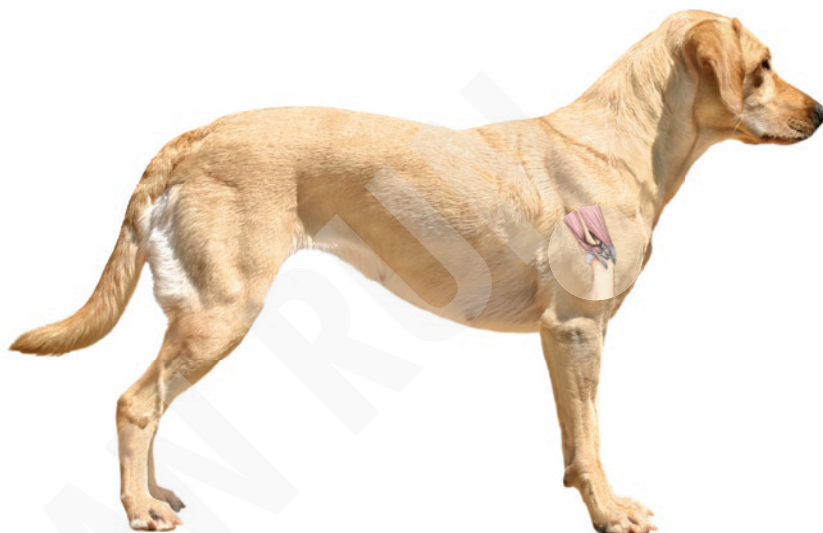> Supraspinatus Tendinopathy

In humans and dogs, several degenerative disorders of the supraspinatus tendon have been identified, including rotator cuff tears, calcifying tendonitis (inflammation) or tendinosis (microtears), and tendinosis as a result of overuse. Degeneration of the supraspinatus tendon is thought to be a factor in the development of rotator cuff tears in humans. Good evidence indicates that overuse is likely an important factor in this disorder. At the cellular level, affected tendons contain discontinuous, disorganized fibers, and typically, no inflammation is detected. In chronic cases, a rapidly growing nodule develops that can impinge on the biceps brachii tendon and cause pain.


The supraspinatus muscle extends the shoulder and advances the limb. The muscle is important to stabilize and prevent collapse of the shoulder joint and is active during 65% to 80% of the time when the dog is standing.



© CINDY TELLEY



Because he's not just a pet.
He's an athlete.



Veterinary Orthopedic and Sports Medicine Group (VOSM) is committed to providing the highest quality veterinary Orthopedic surgery and rehabilitative care. VOSM is the only practice in North America with a:

- Board Certified Orthopedic Surgeon certified in Canine Rehabilitation
- Veterinarian and Physical Therapist also trained in Canine Rehabilitation
- Veterinary Sports Trainer

Through the effective integration of science, compassion, and professional integrity, we relieve pain, regain movement, restore function, and promote health and wellness in your flourishing athlete. **We not only understand the demands that are placed on your pet, we specialize in them.**

- Sports Medicine
- Minimally Invasive Orthopedic Surgery
- Gait Analysis & Retraining
- Rehabilitative Therapy

Entrust your best friend with the best in medical care.



10975 Guilford Road, Annapolis Junction, MD 20701 • 240-295-4400 or 410-418-8446 • www.VOSM.com • info@VOSM.com

Diagnosis

Agility Dogs with supraspinatus tendinopathies commonly have weight-bearing lameness on one side that becomes worse with activity and often is resistant to treatment. The supraspinatus muscle may be atrophied and direct palpation over the tendon and flexion of the shoulder may cause pain. Concurrent BT or shoulder instability may be present, so a thorough shoulder examination by an orthopedic specialist is required.

MRI readily demonstrates the condition in the acute phase. Plain x-rays and CAT (computerized axial tomography; reveals a cross-section of an internal body structure) scan may reveal mineralization in chronic cases. Arthroscopic exploration may demonstrate impingement of the biceps tendon secondary to supraspinatus tendon swelling as well as possible shoulder instability.

Causes

The cause of this injury in Agility Dogs appears to be related to repeated strain injury. This includes hitting the ground or agility contacts on an outstretched forelimb, slipping, overstretching, or overuse of the muscle, quick turns and repetitive eccentric contractions (contractions during lengthening of the muscle), as well as concentric contractions (contractions with shortening of the muscle) with the muscle in lengthened state.

Treatments

Treatment for acute cases consists of conservative medical management (controlled activity and NSAIDs) and rehabilitation therapy (laser therapy, acupuncture, and passive ROM with progression to stretching and strengthening exercises) as described for BT. As with BT, the inflammatory process should be reinitiated in chronic cases and follow a similar rehabilitation protocol.

Surgical treatment is warranted for chronic cases that do not respond to conservative medical management and rehabilitation therapy. Surgical treatment should include arthroscopic exploration to identify and treat possible concurrent BT and/or shoulder instability, or removal of abnormal tissue through an open approach. Surgery has been considered the treatment of last resort in humans with tendinosis because of the small reported difference in treatment success between surgical intervention and conservative management.

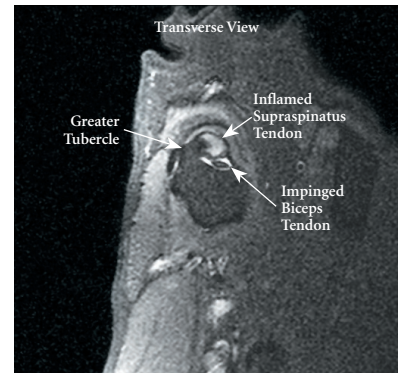
Rehabilitation

Controlled activity, retraining, and preventive techniques for acute and chronic supraspinatus tendinopathy is similar to that used for bicipital tenosynovitis.

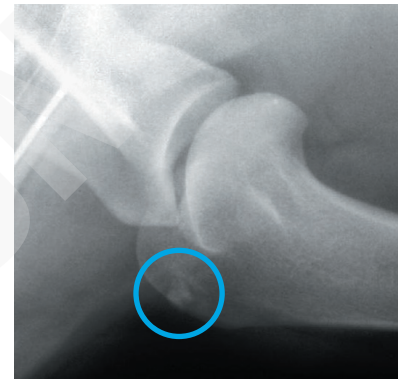
Performance dogs can have a wide range of sport-related conditions of the shoulder. If management of the canine athlete's shoulder is approached from a sound knowledge base of the structure and biomechanics of the region and of the sport involved, success with this challenging region can be enhanced. For more information regarding these conditions, please contact Dr. Canapp at scanapp@vetsportsmedicine.com. 🐾

Additional Reading

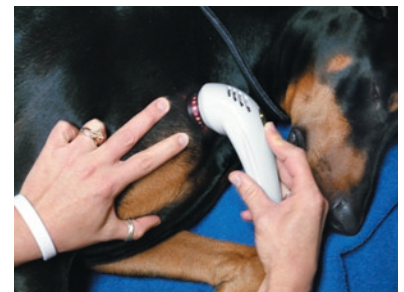1. Gilley RS, Wallace LJ, Hayden DW: Clinical and pathologic analyses of bicipital tenosynovitis in dogs. *Am J Vet Res* 63:402-407, 2002
2. Sharma P, Maffulli N: Tendon injury and tendinopathy: healing and repair. *J Bone Joint Surg Am* 87:187-202, 2005
3. Maganaris C, Narici M, Almekinders L, et al: Biomechanics and pathology of overuse tendon injuries: Ideas on insertional tendinopathy. *Sports Medicine* 34:1005-1017, 2004



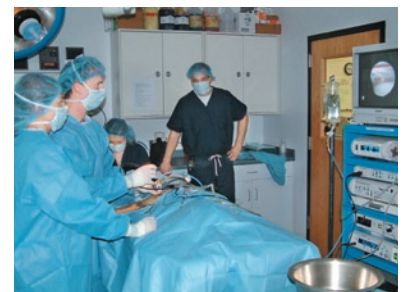MRI showing inflammation within the supraspinatus tendon and impingement of the biceps tendon.



X-ray showing mineralization within the tendon which occurs in chronic tendon conditions.



Supraspinatus laser therapy



Shoulder arthroscopy

Dr. Canapp, a Diplomate of the American College of Veterinary Surgeons completed a combined D.V.M./M.S. at Kansas State University, an internship in small animal surgery at the University of Missouri, a three-year residency in small animal surgery at the University of Florida, and training in canine rehabilitation by the Canine Rehabilitation Institute. Dr. Canapp currently practices orthopedic surgery and sports medicine at the Veterinary Orthopedic & Sports Medicine Group (VOSM) in Ellicott City, Maryland, and acts as a consultant to local zoos, police K-9 units, agility, flyball, and disc competition dogs. See additional information about Dr. Canapp at www.vetsportsmedicine.com.