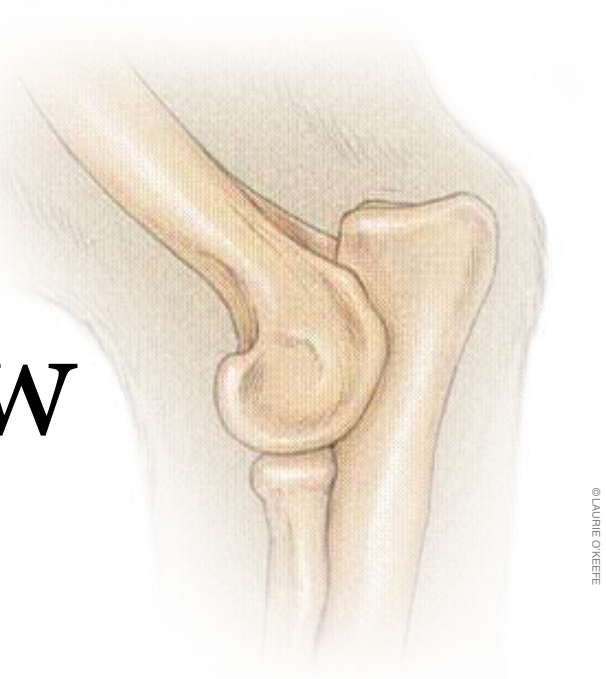


By Sherman O. Canapp Jr., DVM, MS, Diplomate ACVS
Photos by of author, except where noted

Canine Elbow Dysplasia



Elbow dysplasia, the leading cause of forelimb lameness in dogs, is a term used to describe pathology of the elbow joint usually as a result of abnormal bone growth, joint stresses, or cartilage development and includes the presence of one or more diseases of the elbow joint, specifically: fragmented medial coronoid process (FCP)/medial compartment disease (MCD), osteochondrosis (OC) and/or osteochondrosis dissecans (OCD), ununited anconeal process (UAP), and joint incongruity. These conditions may occur individually or in combination within the same joint and often affect both elbows. Although the etiology of these processes is not completely understood, present theory proposes unequal development of the radius and ulna during growth as the underlying cause. Other theories include vascular or cartilage development abnormalities. It is generally accepted that there is a genetic basis and these conditions are heritable. Elbow dysplasia predominantly affects juvenile large to giant breed dogs but is also seen in medium and small breed dogs. However, FCP and elbow incongruity caused by trauma to the growth plates can be seen in any breed.

In this article, we will focus on the presentation, diagnosis, and treatment of chronic elbow dysplasia.

Chronic elbow dysplasia is defined as progressive degenerative joint disease as a result of one or more of the contributing disease processes. This may occur with the primary disease(s) untreated or treated with incomplete healing (incomplete or absence of fibrocartilage formation) or with further fragmentation of the articular cartilage or after secondary degenerative changes were already established at the time of treatment.

History and Clinical Signs

Elbow dysplasia can be insidious in that lameness may be noted with no radiographic evidence of any disease process initially; and conversely, degeneration of the joint can be well established before lameness is apparent. Clinical signs typically manifest between 5 and 12 months of age; however, some dogs may not exhibit lameness for several months to years. The history may also include juvenile lameness that resolved but has returned months to years later. Lameness may be noted in one or both forelimbs. Lameness may be constant upon onset or intermittent, obvious to the point of non-weightbearing or subtle, worsening with or following activity. Rest and/or use of non-steroidal anti-inflammatories may or may not affect the lameness. When standing or sitting, external rotation of the carpus (wrist) and affected elbow(s) is often noted. Circumduction of the affected forelimb(s) may be noted during a walk or trot. On physical examination, the affected elbow may be thickened from bony remodeling and scar tissue. Swelling or effusion (excessive joint fluid) is often seen and incomplete range of motion in flexion is common. Discomfort on flexion and hyperextension, and on direct palpation of the medial (inside) aspect of the elbow is also commonly found.

Diagnosis and Treatment

Along with physical examination, radiographic evaluation is performed to help determine the presence and extent of DJD. Although damage to the articular cartilage cannot be evaluated through radiographs, clues about the underlying cause may be obtained from the radiographs. Further diagnostics are often recommended and include CT or arthroscopy. Arthroscopy offers the advantage of minimally invasive treatment of identified pathology during the same anesthetic event: to include treatment of the primary disease process or stimulation of previously treated pathology with incomplete healing and debridement of secondary degenerative changes.

Chronic elbow dysplasia is defined as progressive degenerative joint disease as a result of one or more of the contributing disease processes.

Post-procedure Care

Following arthroscopic treatment of the elbow, dogs are commonly prescribed non-steroidal anti-inflammatories (NSAIDs) to help decrease inflammation and discomfort. Adequan (Novartis Animal Health), an injectable polysulfated glycosaminoglycans (PS-GAGs) as well as oral joint modifying agents such as Dasuquin (Nutramax Laboratories Inc.), which contains glucosamine, chondroitin sulfate, and avocado/soybean unsaponifiables (ASU), are recommended to help decrease inflammation and potentially slow the progression of osteoarthritis. Elbow rehabilitation after elbow arthroscopy follows a sequentially progressive multi-phased approach. Rehabilitation therapy helps decrease post-operative pain and inflammation, restore range of motion, and improve muscle strength and condition, as well as helps to obtain the best possible long-term comfort and function of the affected joint.

Advanced Treatments

These therapies are beneficial for patients in which the elbow condition was not diagnosed early on and osteoarthritis has already progressed; for dogs intolerant or nonresponsive to NSAIDs; for frequent episodes of acute exacerbation of their underlying elbow disease; or for dogs that have residual postoperative symptoms (effusion, discomfort on range of motion and lameness) despite surgical and/or medical management and rehabilitation therapy and include:

Intra-articular injections (injections directly into the joint) of hyaluronic acid (HA), cortisone, or regenerative stem cell therapy (SCT)

Hyaluronic Acid

Hyaluronic acid (sodium hyaluronate, hyaluronan, HA) is naturally secreted by the joint capsule; however, in an arthritic joint, production and molecular size of HA is decreased. Intra-articular HA is a form of viscosupplementation that restores the physical properties of joint fluid to aid in the lubrication of the joint, decrease inflammation and degradation, and help in cartilage repair. Intra-articular

HA has been widely used in the treatment of OA in horses and humans. Several clinical studies in humans have demonstrated relief of joint pain associated with OA following intra-articular injections of HA. Information regarding the effects of intra-articular HA on naturally occurring OA in dogs is not available; however, several experimental studies using intra-articular HA in dogs have been reported. Results from these studies have demonstrated decreases in pain, lameness, and cartilage degradation. There are several forms of hyaluronic acid available for intra-articular injection; however, at VOSM we prefer Hylartin V (Pfizer), (approved for use in horses and used off-label in dogs), due to its high molecular weight and response to therapy.

Studies evaluating the effects of intra-articular HA in dogs have shown efficacy with three weekly injections. The injections must be given under sterile conditions and may be performed unsedated, sedated, or under general anesthesia depending on the patient. Complications from these injections may include temporary increased pain and lameness and septic arthritis.

Corticosteroids

The benefits of corticosteroids are reduction in inflammation and improved comfort. Methylprednisolone acetate (Depo-Medrol) and triamcinolone acetonide (Vetalog) are most commonly used. We use intra-articular dosing of Depo-Medrol as two injections performed three weeks apart; or one injection of Vetalog. Intra-articular administration of corticosteroids is performed under sterile conditions with the patient unsedated, sedated, or under general anesthesia depending on the patient. Side effects are minimal; however, some dogs show signs of discomfort for the first 12 hours following injection. Administration of Depo-Medrol or Vetalog typically results in pain relief in 24 hours and can last for weeks to months. Studies evaluating the safety and efficacy of long-term treatment in dogs are not well reported.

Regenerative Stem Cell Therapy (SCT)

SCT can also be used in the management of persistent clinical elbow osteoarthritis. Adult regenerative stem cells are multipotent cells located in bone marrow, joint capsule, and fat tissue and are capable of maturing into bone, cartilage, tendon, or ligament cells that can be used to repair and regenerate damaged tissue, such as the cartilage in osteoarthritis. We harvest cells surgically from the fat located behind the shoulder or between the back legs that are sent to Vet Stem (in southern California) where it is purified into regenerative stem cells. Two days after tissue harvest, the regenerative stem cells are returned in sterile syringes and under sedation, the cells are injected into the osteoarthritic joint(s).

Clinical improvement from SCT has been noted in dogs 2-4 weeks after injection and improvement has been seen lasting for up to 2 years. A recent report in Veterinary Therapeutics 2008 evaluated the effect of intra-articular stem cell therapy for the treatment of elbow OA in dogs. This study showed a significant improvement in lameness and range of motion and a significant difference in client evaluation (functional disability scores) in patients treated with intra-articular SCT.

Sliding Humeral Osteotomy (SHO)

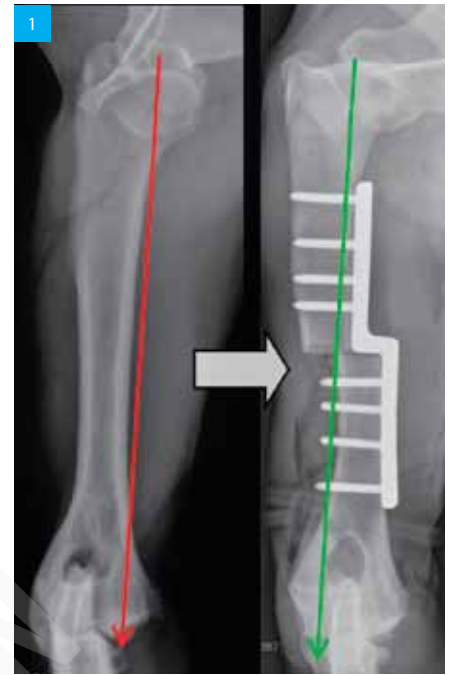
Where extensive erosion of the cartilage surface of the medial compartment of the elbow is evident and producing significant pain and lameness, a SHO may be performed. This procedure is based on similar procedures performed in humans suffering OA of the knee. The procedure realigns the limb to shift the forces off the area of cartilage damage and onto healthy cartilage (thereby relieving the pain of grinding bone on bone) and gives the damaged area the opportunity to heal. A horizontal cut through the midshaft of the humerus is made; then by sliding the bottom portion of the humerus toward the inside of the leg, weight-bearing is distributed toward the healthy lateral portion of the elbow joint. This lessens the load to the arthritic medial aspect of the joint. After the cut in the humerus is made, a spe-

cial plate is applied to the bone, holding it in this new position during healing. As with a traumatic fracture, the bone takes approximately 8 to 12 weeks to heal. Early and long-term clinical follow up both have shown favorable response and second-look arthroscopy has revealed in-growth of cartilage into the eroded areas of the medial compartment as proof of principle unloading. See **Figures 1 through 3**.

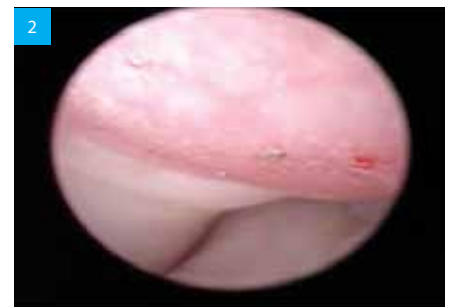Total Elbow Replacement (TER)

TER is an option in dogs with severe OA that have discomfort refractory to any of the above modalities and for dogs in which the lateral compartment is affected eliminating use of the SHO procedure. The first TER system was described in 1996. Since then variations of TER systems have been developed. Presently, the TATE Elbow, developed by Acker and Van Der Meulen, is commercially available. Ten years in development, the impetus for the TATE Elbow was Acker's own yellow Labrador Retriever Tate. Tate developed severe elbow dysplasia and while Acker tried common treatments, the outcome was unsuccessful. Ultimately, the TATE Elbow System became the eventual result.

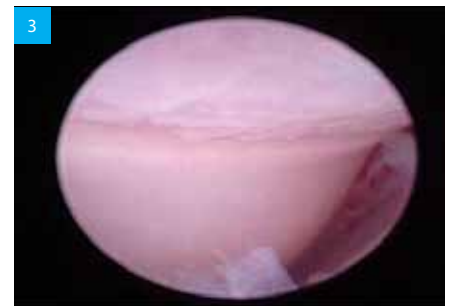
Implementation of the TATE Elbow System was first performed in July 2007. Since then many dogs affected with intractable elbow arthritis have been treated with this new prosthesis. The TATE Elbow System is pressed fit as opposed to a stemmed and cemented system. Long-term stability relies on bone ingrowth into the porous structure of the implants (osteointegration). Cementless prostheses have potential advantages over cemented models, including reduced risk of infection and reduced rate of implant wear, both of which are regarded as leading causes of post-operative failure. Because the components of this system are impacted simultaneously as a pre-assembled cartridge, there is reduced trauma to the patient and accurate alignment and tracking of the prosthetic components throughout range of motion is guaranteed. The patient needs a post-



Radiograph of humerus and elbow joint pre- and post-sliding humeral osteotomy, showing weight-bearing load distribution.



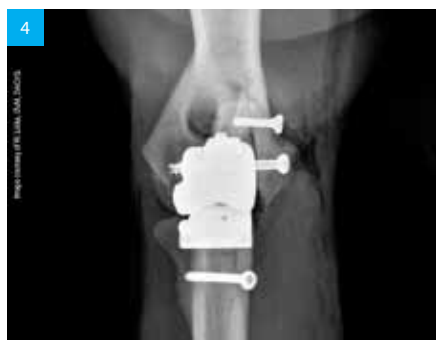Arthroscopic view of medial elbow joint before sliding humeral osteotomy (SHO).



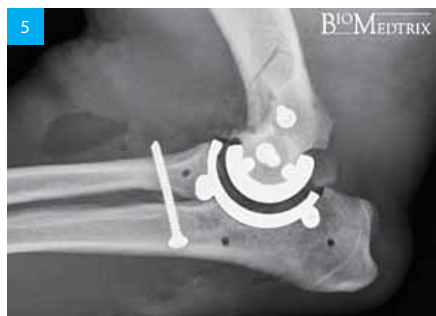Arthroscopic view of medial elbow joint six months after SHO.

Clinical signs typically manifest between 5 and 12 months of age; however, some dogs may not exhibit lameness for several months to years.

operative 8-12 week restorative period for full functional recovery. There are no long-term studies to date evaluating this system. See **Figures 4 and 5**.



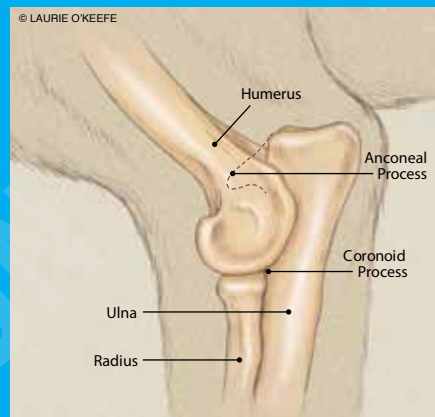
Radiograph of elbow post TER (AP view). Courtesy of BioMedtrix



Radiograph of elbow post TER (lateral view). Courtesy of BioMedtrix

Anatomy

The canine elbow is responsible for flexion and extension of the forelimb. Consisting of the convergence of three bones (the humerus, radius, and ulna), the elbow is a complex joint. The articular surfaces of these bones are covered by cartilage. The joint capsule surrounds this junction and provides mechanical and nutritional support including secreting joint fluid. Joint fluid lubricates and cushions the articular surfaces of the bones assisting in smooth articulation during movement. There are two rounded protuberances at the end of humerus forming the lateral and medial aspects of the humeral condyle. Between the lateral and medial aspect of the humeral condyle is a hole into which the anconeal process, a beak-like protrusion of the ulna, fits during extension of the forelimb. The humeral condyle rests on the coronoid process of the ulna. The coronoid process is comprised of a smaller lateral aspect and larger medial aspect. There should be a smooth transition from the ulnar articular surface to the radial surface. All the components must fit together precisely to form a healthy joint.



Conclusion

Elbow dysplasia is a devastating disease. Early identification and treatment of elbow disease are essential for the best possible long-term health of the joint. Unfortunately, early identification can be challenging due to the lack of correlation between the severity of clinical signs and radiographic findings. This is a great source of frustration as a delayed diagnosis can have a profoundly negative effect on prognosis. Therefore, a thorough physical examination including gait analysis, good radiographic technique, careful scrutiny of the films by a knowledgeable practitioner, and arthroscopic evaluation of the joint if any elbow disease is suspected provides the greatest opportunity for appropriate diagnosis, treatment, and improved prognosis for the dog.

Dr. Canapp, a Diplomate of the American College of Veterinary Surgeons, completed a combined DVM/MS at Kansas State University, an internship at the University of Missouri, a residency in small animal surgery at the University of Florida, and training in canine rehabilitation by the Canine Rehabilitation Institute. Dr. Canapp practices orthopedic surgery and sports medicine at the Veterinary Orthopedic & Sports Medicine Group (VOSM) in Annapolis Junction, Maryland, and acts as a consultant to regional zoos, police K-9 and search and rescue units, and national agility, flyball, and disc dog organizations. Dr. Canapp was the founding President of the American Association of Rehabilitation Veterinarians and publishes and lectures frequently at an international level on sports medicine and minimally invasive surgery. See additional information about Dr. Canapp at www.vosm.com