

Foot and Pad Care for Agility Dogs



© CLEAN RUN

By David L. Dycus, DVM, MS, CCRP, DACVS-SA and Debra A. Canapp, DVM, CCRT, CVA, DACVSMR.

Photos courtesy of VOSM except where noted.

One of the easiest ways to avoid a serious pad or foot injury in our canine athlete is by simple prevention, including regular pad and foot exams at home or at competition. Each time your dog engages on a risky surface, including hard, compact dirt, asphalt/concrete, synthetic surface or field terrain, the paws should be checked for potential problems. By checking each digit fully, including each pad, the area between the digits, the nail, and the nail bed, and placing the joints through gentle range of motion, you can detect problems earlier and provide better supportive care in hopes of circumventing a more serious injury.

Common paw problems seen amongst our performance dogs include split toenails, skin and nail bed abrasions, penetrating foreign objects, digit collateral ligament injuries, pad abrasions, lacerations, and sloughing of the pad's tough surface.

An initial approach to prevention of pad injury is carefully and gradually exposing your dogs' feet to different surfaces; such as rough natural surfaces like sand or packed dirt, and synthetic surfaces such as cool concrete, cement, rubber, Astroturf, etc. The key in toughening up the pads is to gradually increase the exposure time to these surfaces, ultimately avoiding any breakdown of the tissue. Even with "tough pads," pad inju-

ries can still transpire, but often require more extreme exposure times and surfaces that can often be avoided.

Keeping long hair properly trimmed around the pads and toes will also help in prevention of foot injury. This will allow the pad to be fully exposed and aid in the natural grip, thus preventing any unwanted slips or falls. This inter-digital hair, left unkempt, may also collect foreign material or snow that in turn may abrade the sensitive skin in these areas, leading to swelling and infection.

Proper toenail length is also vital in maintaining normal digit biomechanics, grip and balance on any surface. Toenails that are too long run the risk of splitting, creating an opportunity for severe swelling and infection.

Digital Collateral ligament damage can also occur from a primary injury or excessive work over time.


Challenging Surfaces

Indoor Dirt Arena

Dangers: hidden rocks and sticks, mud build-up

The indoor dirt arena may seem like the safest surface available to the agility dog, but hidden dangers can arise on any surface. The dirt arena poses two unique threats that we don't always think about, but these dangers can be easy to address. The indoor dirt arena can cause our dogs' paws to become caked with mud. This might be only slightly uncomfortable or irritating initially, but as the mud dries it can have sharp edges with the potential to cause cuts or punctures.

Rocks or pebbles are another concerning factor of the indoor dirt track. Pebbles can become lodged in the dog's paw, which can be very uncomfortable and may



Proper nail trims and trimming the hair around the pad can be helpful in making sure that the pads are used properly on surfaces.

cause a visible lameness or cause the dog to cry out in pain. Even the most stoic of dogs can be greatly affected by a small pebble.

The good news is that these two dangers can be addressed quite easily by providing your dog with a “paw check” after every run and throughout the day as you move around the arena. A thorough check of each paw, from toes to elbow and between each digit, can provide us with small piece of mind against caked-on mud and tricky pebbles. If your paw check turns up any cuts, or you see a lameness that does not resolve after removing a pebble from the toes, be sure to seek veterinary care.

Extensive training on dirt can also be very drying on the paws. A gentle moisturizer applied after your paw check and cleaning can be a protective and pampering way to keep the paws in good condition. Check with your veterinarian for recommendations on moisturizers and cleansers.

Asphalt/Cement

Dangers: temperature, chemicals, abrasiveness

Asphalt and cement may not seem like part of your agility routine, but they are everywhere, including the entrance to many agility competitions. Your home sidewalk, the arena parking lot, and your neighborhood Saturday morning stroll can all pose the same problems for your canine competitor. Asphalt and cement can be considerably hotter than their surroundings in the summer months, and should be approached with caution. If you think the ground would be too hot for your own feet, then it’s also too hot for your dog’s paws. While walking can’t always be avoided, try to train at cooler times of the day, like early morning or later in the evening when the sun is not heating the pavement. If you notice any burning or blistering, seek veterinary care right away. Prevention is the best defense when talking about hot pavement.

While the summer months pose the threat of heat, the winter months have their own dangers—harmful chemicals in ice-melt and the ice itself. Ice can easily build up on your dog’s paws

while he is walking the neighborhood or romping through the yard. Ice-melt can also contain dangerous chemicals that can burn or sting your dog’s paws, and are especially bothersome if he has any cuts. Ice-melt should also not be ingested. Fortunately, these common problems can be solved by cleaning the paws with room-temperature water and a soft cloth. Clean the paws thoroughly after any outside play, and keep a travel option with you for easy cleaning when you arrive at your destination. If you suspect excessive cold that could be frostbite, or you suspect that your dog has ingested ice-melt, seek emergency veterinary care as these can have serious, permanent consequences.

Fields

Dangers: hidden rocks and sticks, bugs, chemicals, hidden holes

Grass can pose the same risks of hidden pebbles and chemicals like dirt and asphalt, but it poses a few new problems, too. Grass can be riddled with bugs—from bees and wasps to ants and spiders, our natural world can be full of dangerous, crawling critters. Just like stings and bites are painful for us, they’re also painful for our dogs. Bees, wasps, ants, spiders, and other bugs all pose unique threats in histamine reactions and potential serious allergic reactions. The best course of action after a bite or sting for your dog is to seek medical attention—even if the reaction is minor, it could quickly turn into a serious situation.

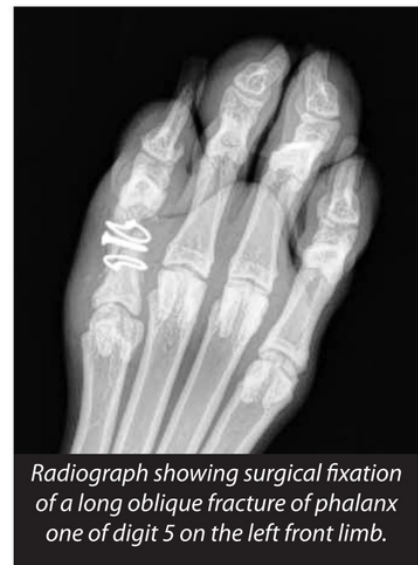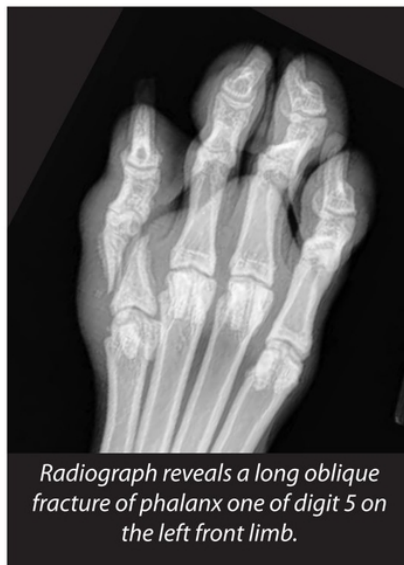Hidden holes in grassy surfaces can be orthopedic nightmares. They create the opportunity for your dog to pivot in a hole, which could result in serious soft tissue and bone damage.

How to Recognize and Treat Advanced Foot and Pad Injuries

Digit Fractures

Digital fractures can occur in a number of ways during competition, training, or play. In many scenarios it is not known how the digit fractures occur, but certain causes such as a sharp turn when the toe is in an otherwise fixed position, stepping in a hole, and knocking the digits on hard surfaces (rocks, tree stumps, etc.) can be culprits. With digital fractures comes pain and, in many cases, the dog will initially hold the leg up. While examining your dog, you may note extreme pain with manipulation of the fracture. Within a few hours, the toe will tend to become very swollen and even lead to swelling of the foot. Ice can be applied to area to help minimize the swelling and reduce pain.

Veterinary care should be sought for a full orthopedic examination. Veterinarians may have a clinical suspicion of a fractured digit based on the examination alone,



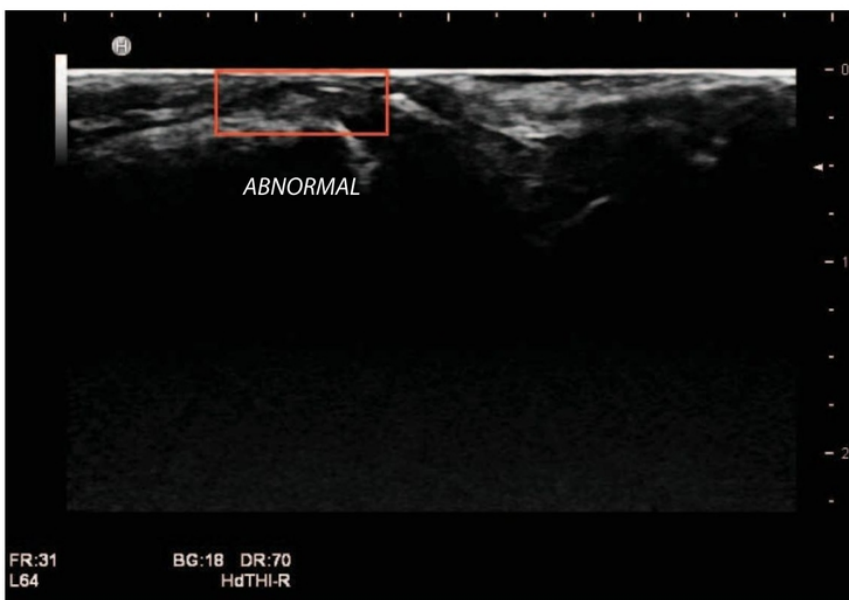
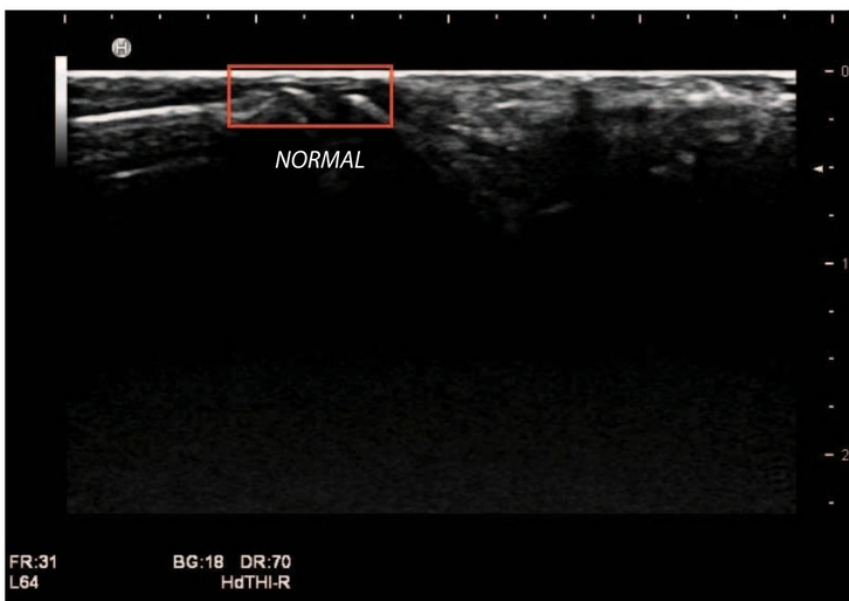
but radiographs (X-rays) will be needed to fully diagnose the fracture. A bone can fracture in many different configurations, so being able to see it on a radiograph is important so that the appropriate treatment can be instituted. Depending on the configuration of the fracture, the digit affected, the time since the fracture, and the size of your dog, several options exist for treatment. In some cases, simply placing a splint to help immobilize the fracture may be recommended. However, it should be noted that to truly immobilize the digit is very challenging and thus even with a splint there is still micromotion present, which may explain the longer duration of healing with digital fractures. In other cases, surgery may be recommended to stabilize the fracture and facilitate quicker healing. Unfortunately, fixation of digital fractures is limited to only medium to large breed dogs because of the availability of implant size.

Regardless of the way the fracture is stabilized, radiographs should be completed every four weeks to ensure healing in a timely manner. The average bone should heal in about 8-12 weeks; however, it is not uncommon for digital fractures treated with a splint to take 12 weeks or longer to heal. In severe cases where the fracture is not repairable and the damage is too great for healing to be expected, then digital amputation may be recommended to eliminate the source of discomfort. Alternatively, if a digital fracture has been treated with a splint and has progressed to a non-healing fracture, then amputation may be recommended.

Digital Collateral Ligament Injuries

Besides fractures, the next most common toe injury seen in sporting dogs is collateral digit sprains. These often occur during fast, sharp turns on uneven or slippery terrain. Toes are often splayed out to gain as much traction as possible. In this situation, the toe may experience significant torque at an unnatural angle, resulting in extreme forces placed on these collateral ligaments. The outcome may range from minor bruising to a significant sprain or rupture of these small ligaments. Unfortunately, even though they are small, they often cause sig-

nificant discomfort to the athlete, thus causing moderate lameness and altered gait. This change, itself, may even result in further injury of other joints due to the biomechanical change in the patient's stride or weight bearing in the affected limb. Unfortunately, these ligaments frequently do not heal well on their own, and additionally require a significant time to form fibrous scar tissue in the area of the injury. Healing time usually demands anywhere from one to four months depending on the degree of injury or prior osteoarthritis in the area. In these situations, once identification of this injury is obtained through diagnostic ultrasound imaging, there are methods to aid in comfort and quicker return to sport for these patients.



Grade 2 sprain of the lateral collateral ligament of the digit. Images show both normal and abnormal anatomy highlighted, as seen on diagnostic musculoskeletal ultrasound scan.

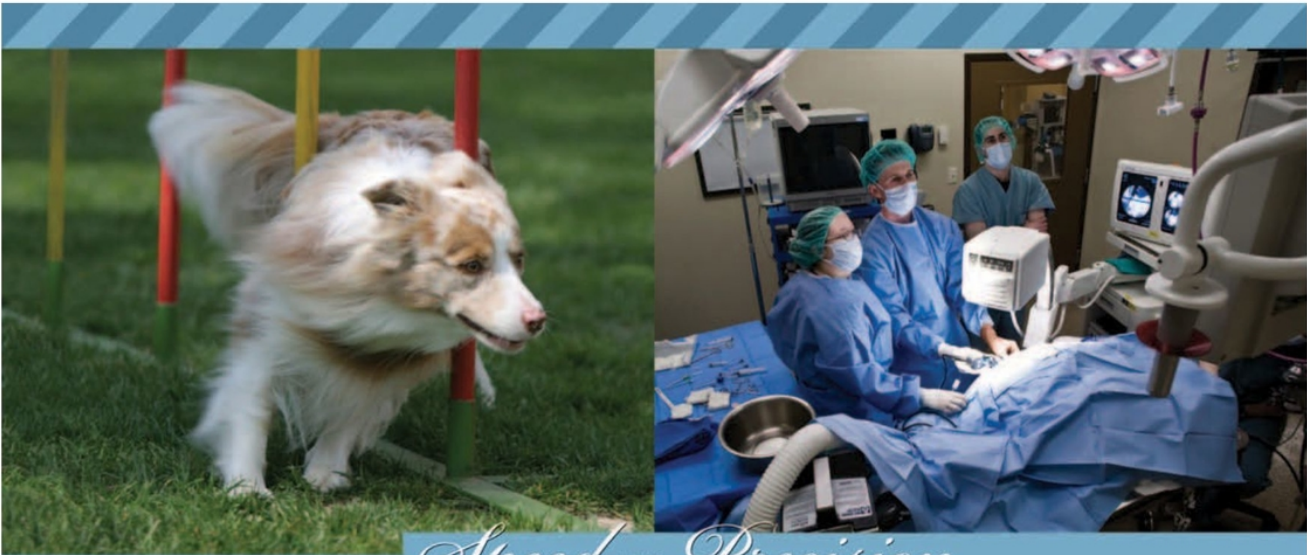


A protective wrap is worn to prevent further damage or irritation during the healing phase after soft tissue injury. Wraps are placed on both feet to prevent the dog from focusing on the injured foot.

One method used to aid in comfort is providing support to prevent further damage or irritation during this healing phase. This support is a simple two to three layers of an elastic, non-stick vet wrap. This wrap can be changed daily or even taken off during times of rest. It should be placed with enough tension to restrict any lateral toe movement, but not so tightly as to cause any abrasions or swelling. The wrap is often placed on both feet in order to help the dog not focus on the injured limb. In extreme situations, where healing is prolonged with significant discomfort, regenerative medicine (stem cell therapy and/or platelet rich plasma (PRP) or small amounts of anti-inflammatory injectable medication can be injected via ultrasound guidance into the injured area to aid providing the patient with comfort more quickly. 🐾

Debra A. Canapp, DVM, CVA, CCRT, DACVSMR became a board-certified diplomate with the American College of Veterinary Sports Medicine and Rehabilitation in 2012. Her area of interest, clinical work, lecturing, and research focus on sports medicine and rehabilitation therapy—specifically canine sports-related injury, sport rehabilitation, and performance. Dr. Canapp has completed advanced courses in canine rehabilitation, hydrotherapy, acupuncture, sports medicine, orthopedics, and stem cell therapy. Currently, Dr. Canapp practices sports medicine, acupuncture, musculoskeletal ultrasound, and rehabilitation therapy at Veterinary Orthopedic & Sports Medicine Group in Annapolis Junction, Maryland, where she is also co-principle and medical director. To learn more about Dr. Canapp, please visit www.VOSM.com.

David L. Dycus, DVM, MS, CCRP, DACVS-SA attended Mississippi State University's College of Veterinary Medicine. After earning his Doctor of Veterinary Medicine, he then completed a rotating internship, and returned to Mississippi State for his surgical residency, simultaneously completing his Master of Science. Dr. Dycus then earned diplomate status with the American College of Veterinary Surgeons. Dr. Dycus is also a Certified Canine Rehabilitation Practitioner through the University of Tennessee. With these skills, Dr. Dycus currently practices orthopedic surgery and sports medicine at Veterinary Orthopedic & Sports Medicine Group in Annapolis Junction, Maryland. Dr. Dycus has special interests in orthopedics and sports medicine, and frequently lectures to fellow veterinarians on these topics at both local and national conferences. To learn more about Dr. Dycus, please visit www.VOSM.com.



Speed AND Precision

ARE THERE OBSTACLES to your athlete's performance? Veterinary Orthopedic & Sports Medicine Group will make a diagnosis quickly and accurately, getting your athlete back on course. VOSM is committed to providing the best veterinary orthopedic, sports medicine, and rehabilitative care for your agility dog by utilizing the most advanced veterinary practices, techniques, and equipment available. Call us today, or visit www.VOSM.com to learn more.

- Sports medicine
- Diagnostic musculoskeletal ultrasound
- Arthroscopic & orthopedic surgery
- Regenerative medicine & stem cell therapy
- Spine center specializing in neurologic conditions
- Objective gait analysis system



10975 Guilford Road, Annapolis Junction, MD 20701

240-295-4400